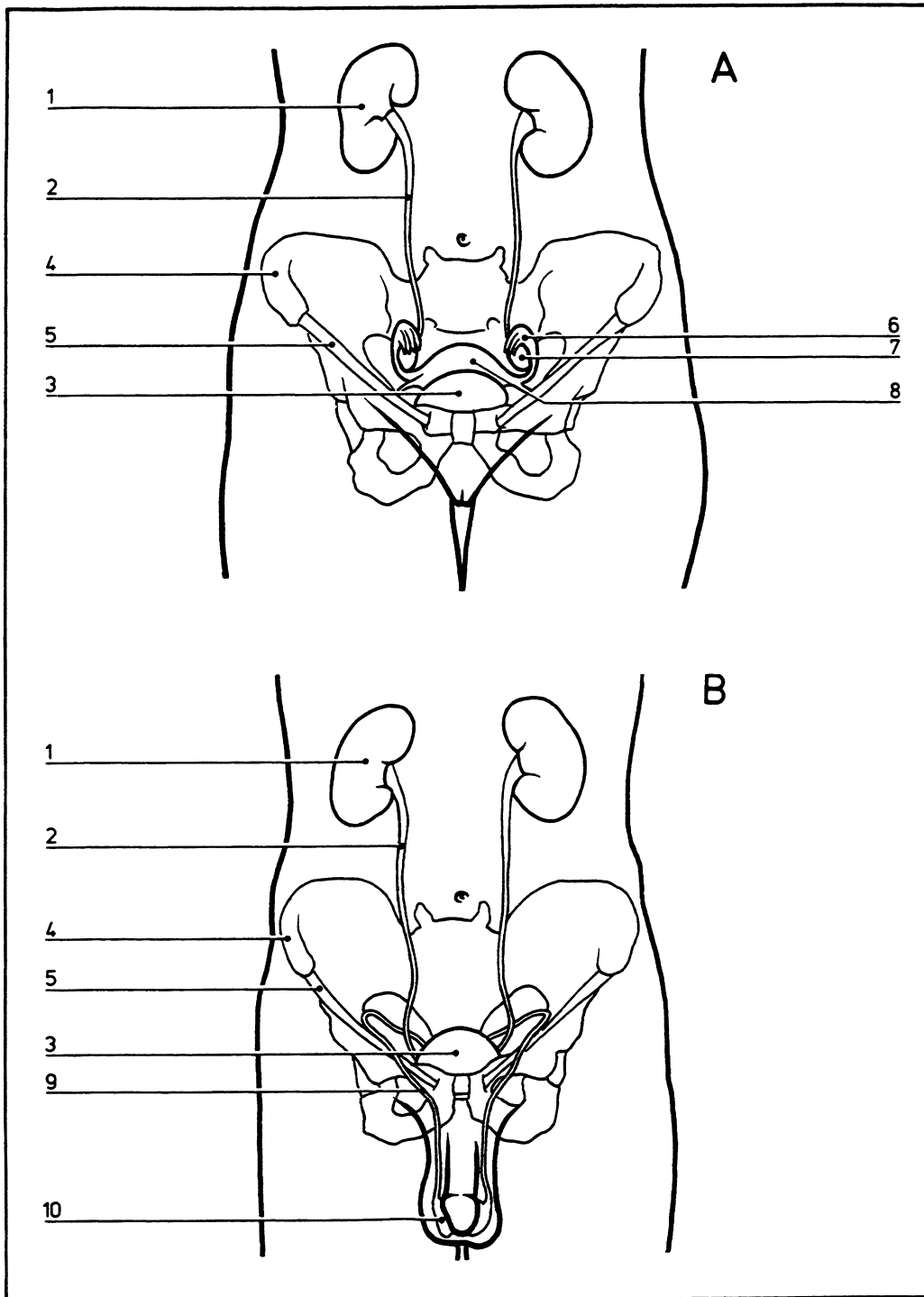


**Key diagram: 2**

09.002



- |          |                                                  |           |                   |
|----------|--------------------------------------------------|-----------|-------------------|
| <b>A</b> | Anterior view of female urinary tract and pelvis | <b>5</b>  | Inguinal ligament |
|          |                                                  | <b>6</b>  | Fallopian tube    |
|          |                                                  | <b>7</b>  | Ovary             |
| <b>B</b> | Anterior view of male urinary tract and pelvis   | <b>8</b>  | Uterus            |
|          |                                                  | <b>9</b>  | Vas deferens      |
|          |                                                  | <b>10</b> | Testis            |
- 
- |          |         |
|----------|---------|
| <b>1</b> | Kidney  |
| <b>2</b> | Ureter  |
| <b>3</b> | Bladder |
| <b>4</b> | Pelvis  |