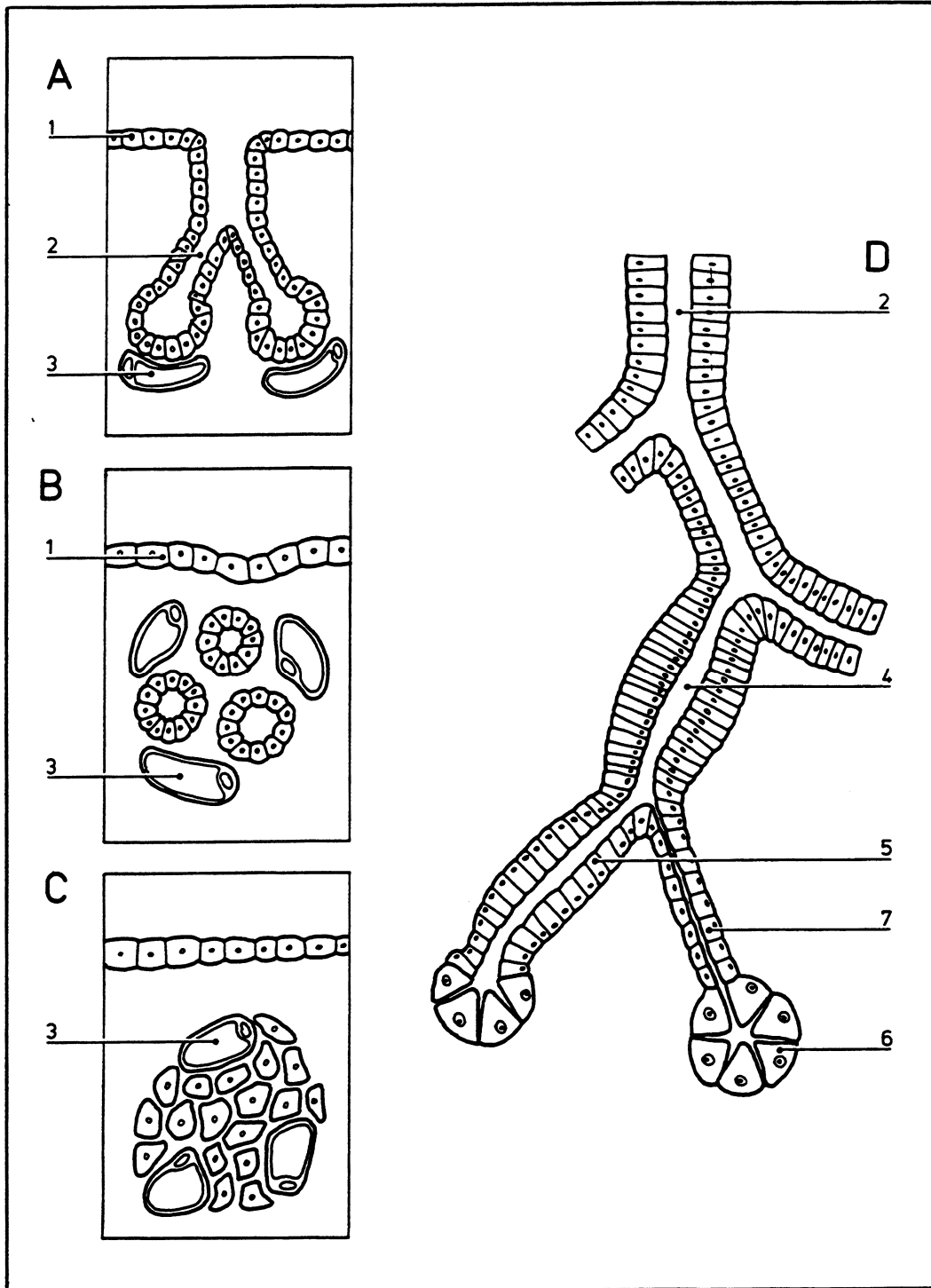


Glands

02.006



- | | | | |
|---|---|---|--------------------|
| A | Schematized diagram of an exocrine gland | 1 | Surface epithelium |
| | | 2 | Excretory duct |
| B | Schematized diagram of an endocrine gland with follicles | 3 | Capillaries |
| | | 4 | Secretion tube |
| C | Schematized diagram of an endocrine gland without follicles | 5 | Tubulus |
| | | 6 | Acinus |
| D | Detailed structure of an exocrine gland (salivary) | 7 | Intercalated duct |
| | | 8 | Capillary |

©DIAGRAM