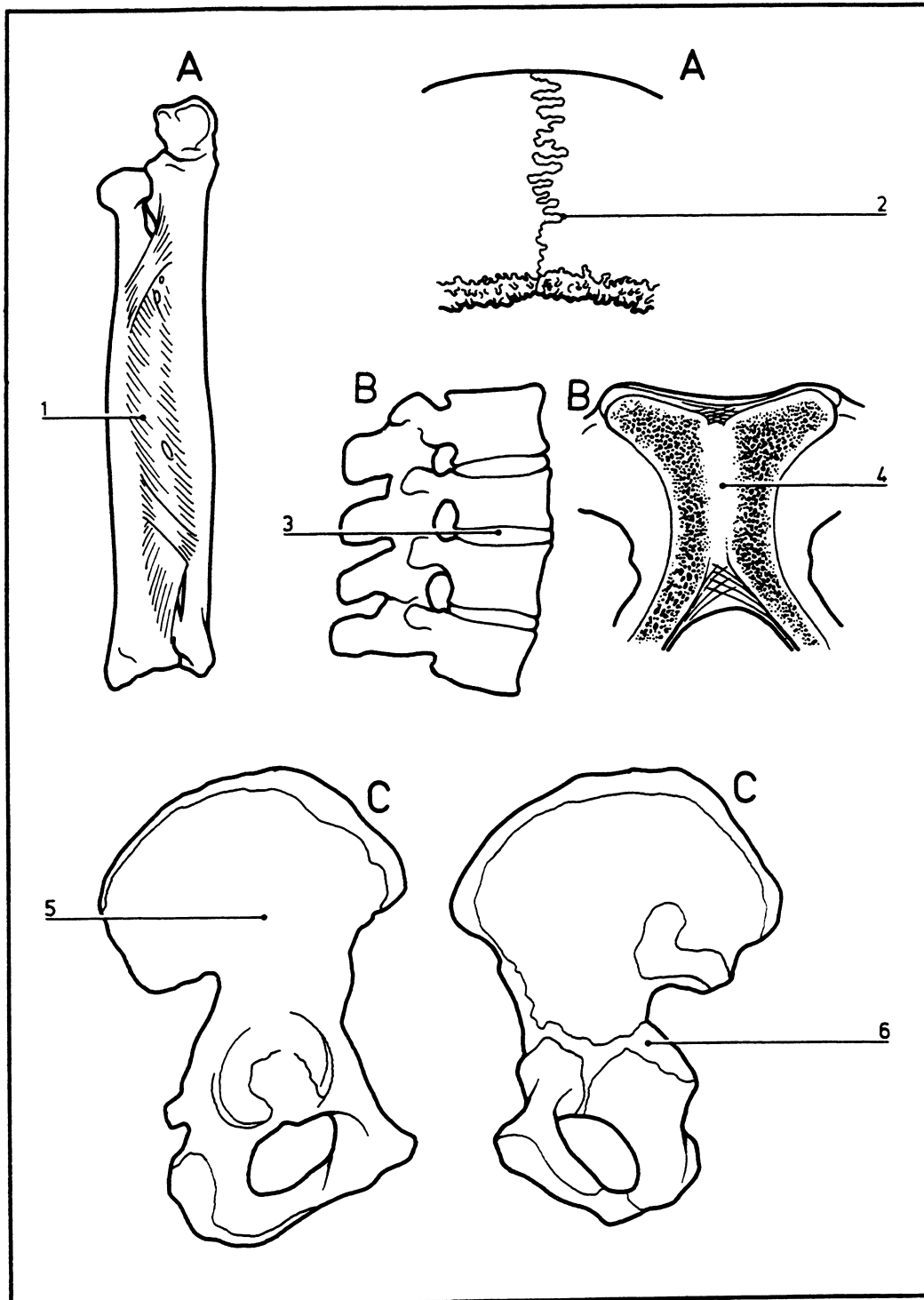


Joints between bones Immovable or Slightly Movable

05.004



©DIAGRAM

- | | |
|--|---|
| A Syndesmosis (fibrous joint) | 4 Symphysis pubis |
| B Synchondrosis (cartilaginous joint) | 5 Lateral view of hip bone – cartilage joints have fused |
| C Synostosis | 6 Medial view of hip bone – cartilage joints present |
| 1 Interosseous membrane in forearm | |
| 2 Sagittal suture in skull | |
| 3 Intervertebral disk in spine | |