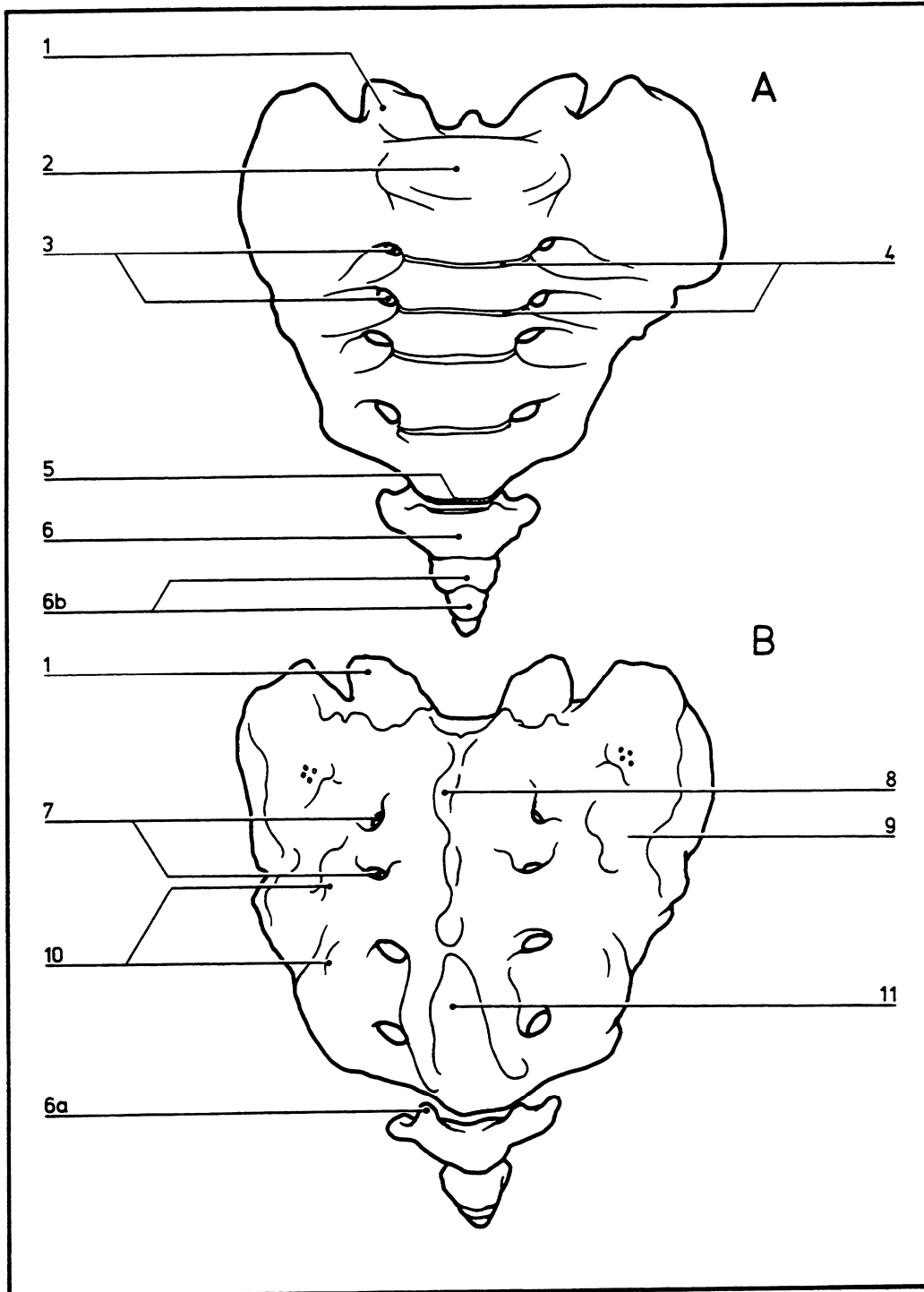


Sacrum and coccyx

05.015



- | | |
|-------------------------------------|---------------------------------|
| A Anterior view | 6a Cornua |
| B Posterior view | 6b Coccygeal vertebrae |
| 1 Superior articular process | 7 Dorsal sacral foramina |
| 2 Base of sacrum | 8 Median sacral crest |
| 3 Anterior sacral foramina | 9 Pars lateralis |
| 4 Transverse lines | 10 Lateral sacral crest |
| 5 Apex of sacrum | 11 Sacral hiatus |
| 6 Coccyx | |