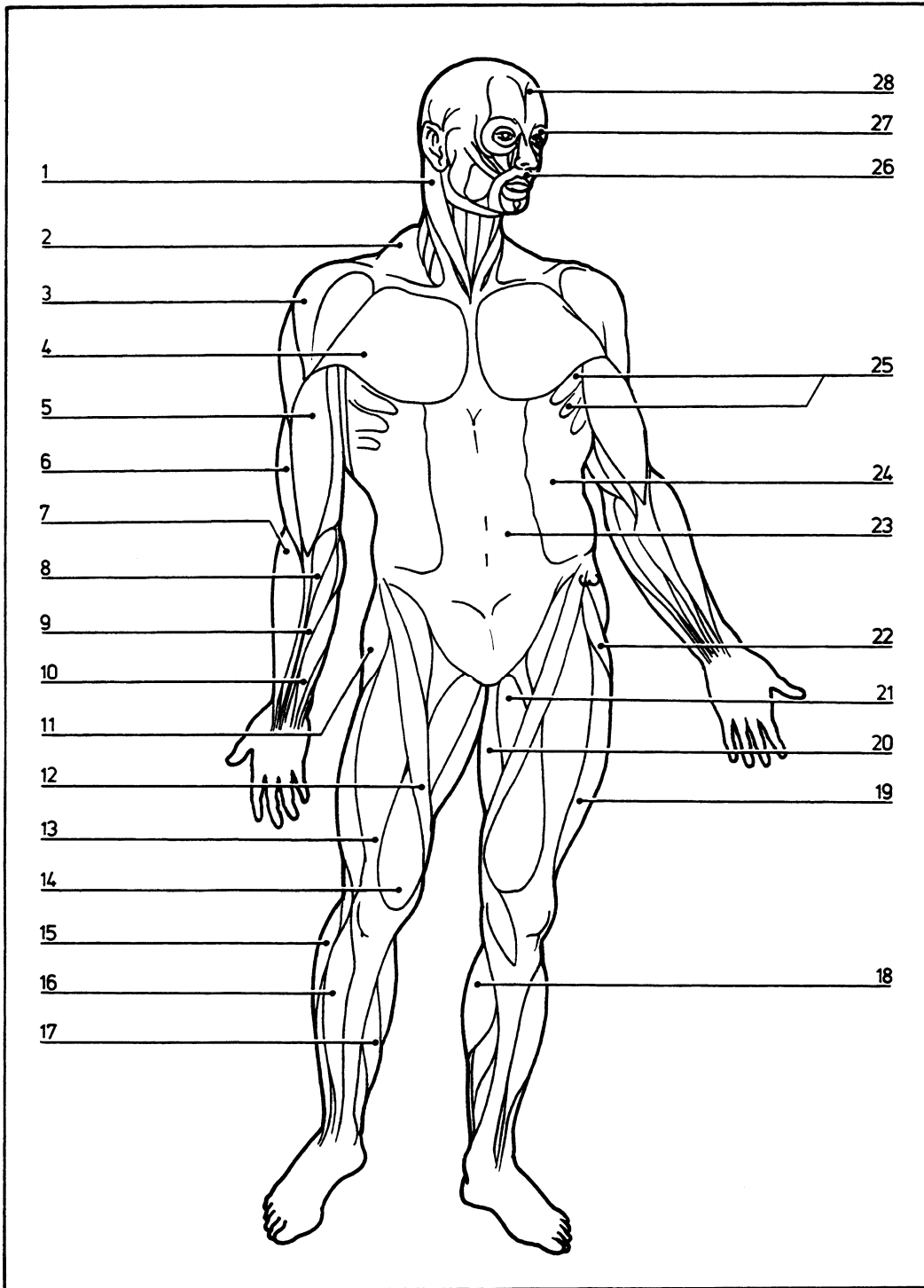


Key diagram: 1

04.001



Anterior view of superficial muscles

- 1 Sternocleidomastoid
- 2 Trapezius
- 3 Deltoid
- 4 Pectoralis major
- 5 Biceps brachii
- 6 Brachialis
- 7 Brachioradialis
- 8 Flexor carpi radialis

- 9 Palmaris longus
- 10 Flexor digitorum superficialis
- 11 Gluteus medius
- 12 Sartorius
- 13 Rectus femoris
- 14 Vastus medialis
- 15 Peroneus longus
- 16 Tibialis anterior
- 17 Soleus
- 18 Gastrocnemius

- 19 Vastus lateralis
- 20 Gracilis
- 21 Adductor longus
- 22 Tensor fasciae latae
- 23 Rectus abdominis
- 24 External abdominal oblique
- 25 Serratus anterior
- 26 Orbicularis oris
- 27 Orbicularis oculi
- 28 Occipitofrontalis