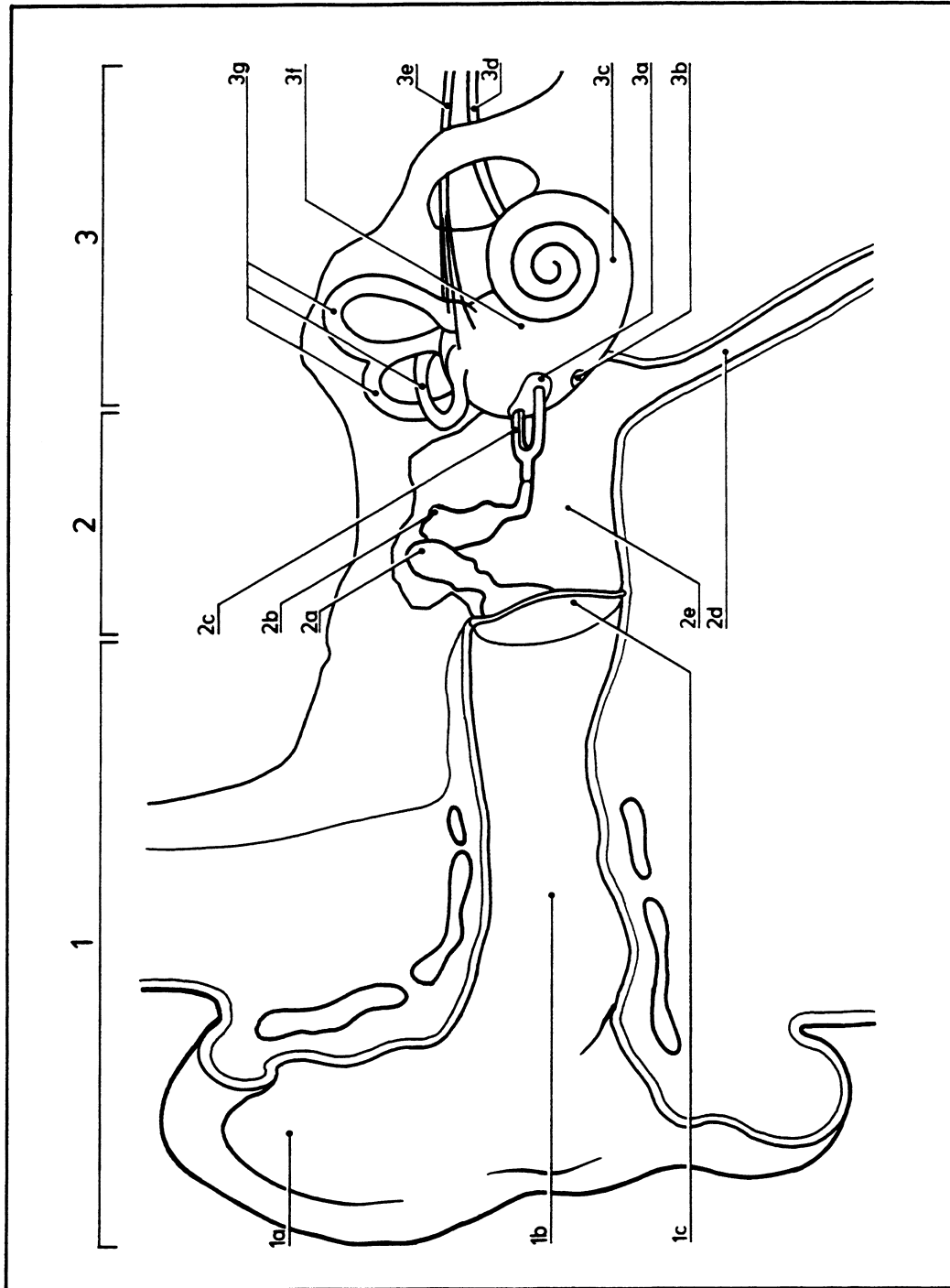


# Ear: 2

11.015



Schematized coronal section through the ear

- 1 External ear
- 1a Auricle
- 1b External auditory meatus
- 2 Tympanic membrane
- 2a Malleus
- 2b Incus
- 2c Stapes
- 2d Auditory (Eustachian) tube
- 2e Tympanic cavity
- 3 Inner ear
- 3a Oval vestibular window
- 3b Round cochlear window
- 3c Cochlea
- 3d Cochlear nerve
- 3e Vestibular nerve
- 3f Vestibule
- 3g Semicircular canals