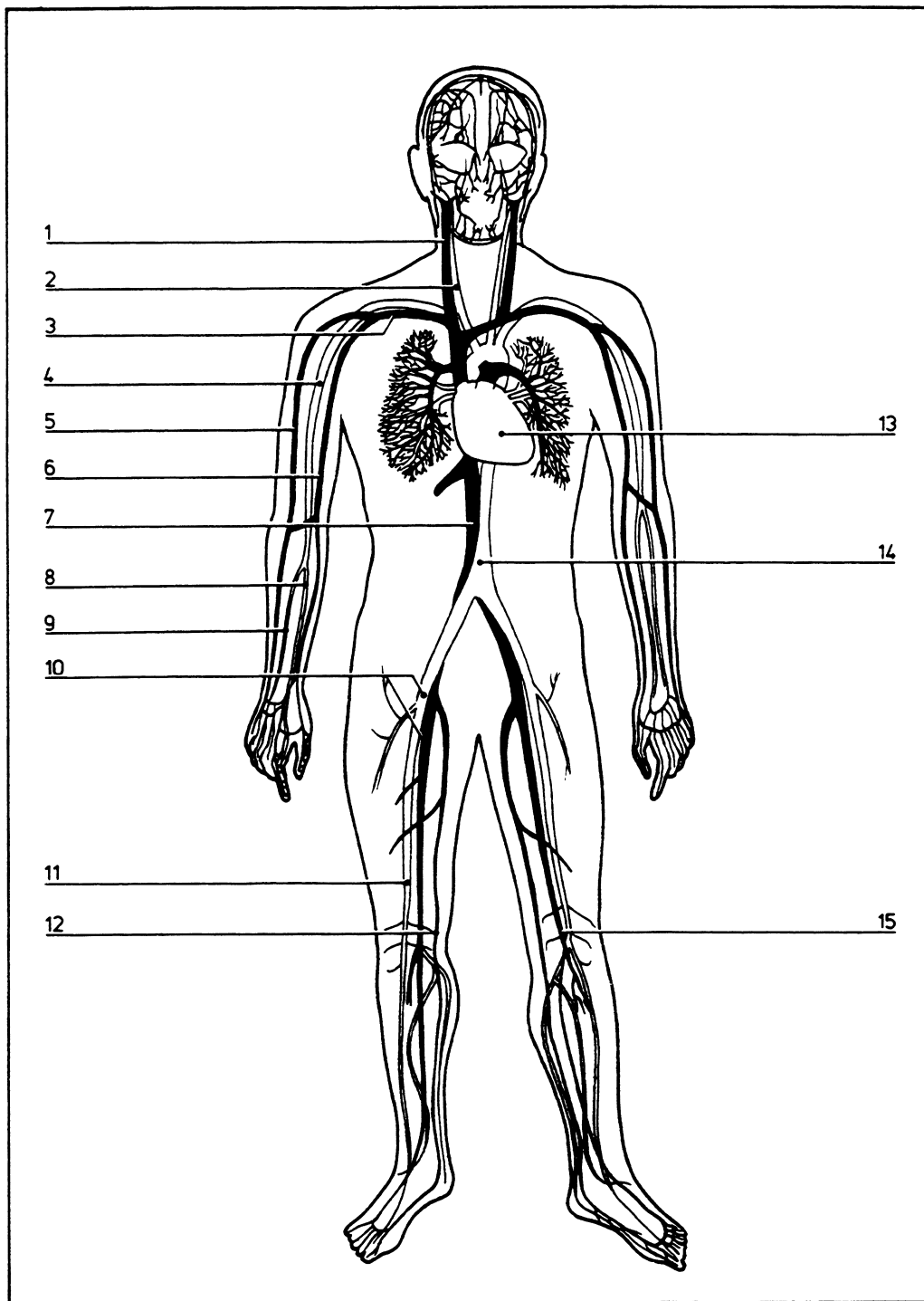


Key diagram

06.001



- | | | |
|--|----|------------------------------|
| Anterior view showing major arteries (white) and veins (black) | 6 | Basilic vein |
| 1 Internal jugular vein | 7 | Inferior vena cava |
| 2 Common carotid artery | 8 | Radial artery |
| 3 Subclavian vein and artery | 9 | Ulnar artery |
| 4 Brachial artery | 10 | Common iliac artery and vein |
| 5 Cephalic vein | 11 | Femoral artery |
| | 12 | Great saphenous vein |
| | 13 | Heart |
| | 14 | Aorta |
| | 15 | Femoral vein |

©DIAGRAM