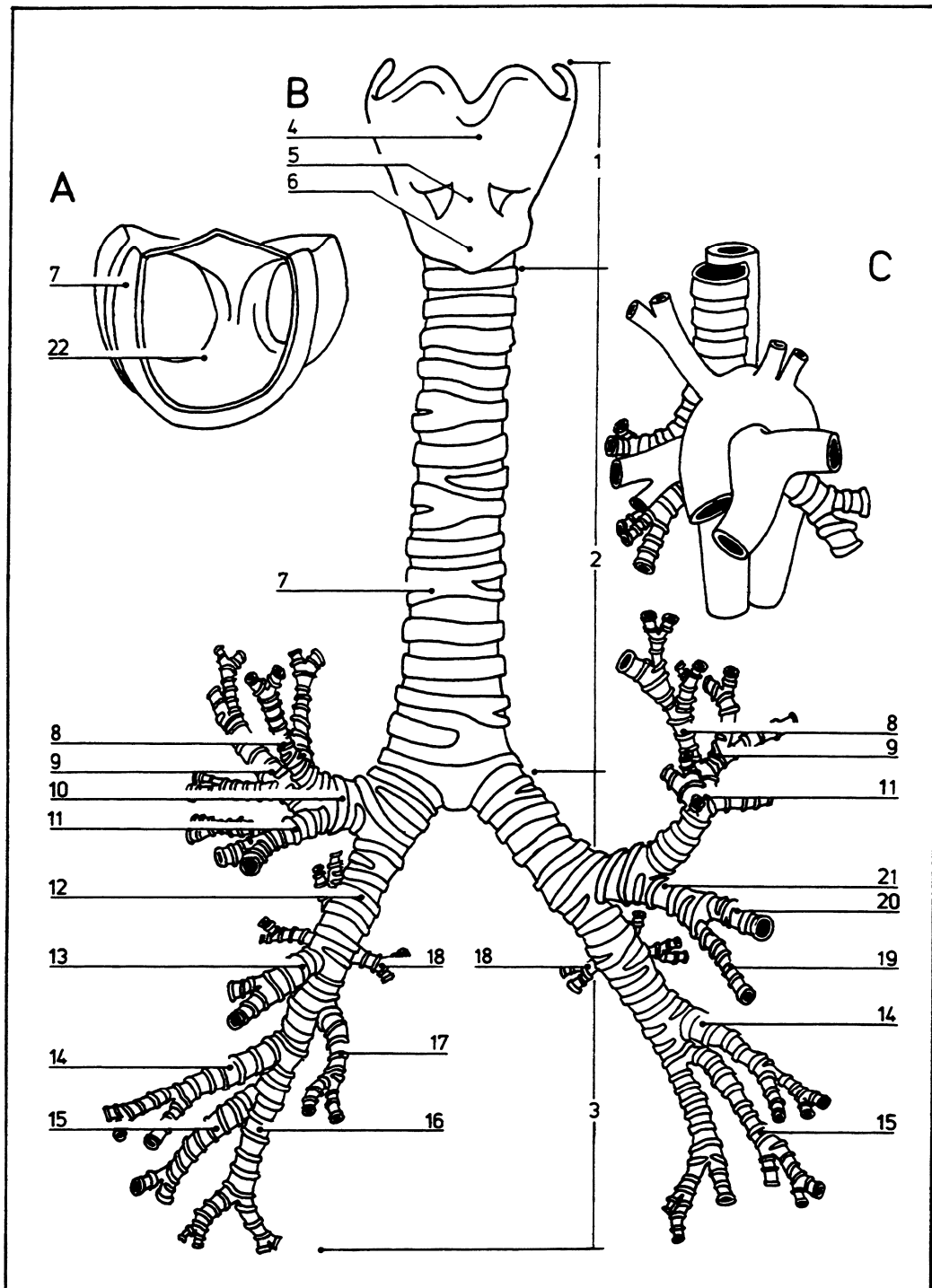


Bronchial tree

07.020



- | | | | | | | | |
|---|---|----|----------------------------------|----|--------------------------|----|---|
| A | Trachea viewed from above toward the carina | 2 | Trachea | 11 | Anterior bronchus | 18 | Superior (apical) bronchus of inferior lobe |
| B | Cartilages of the larynx, trachea, and bronchi | 3 | Bronchi | 12 | Right bronchus | 19 | Inferior lingular bronchus |
| C | Position of bronchial division in relation to great vessels | 4 | Thyroid cartilage | 13 | Middle lobar bronchus | 20 | Superior lingular bronchus |
| 1 | Larynx | 5 | Cricothyroid ligament | 14 | Anterior basal bronchus | 21 | Lingular bronchus |
| | | 6 | Cricoid cartilage | 15 | Lateral basal bronchus | 22 | Carina |
| | | 7 | Cartilage hoops | 16 | Posterior basal bronchus | | |
| | | 8 | Apical bronchus of superior lobe | 17 | Medial basal bronchus | | |
| | | 9 | Posterior bronchus | | | | |
| | | 10 | Superior lobar bronchus | | | | |