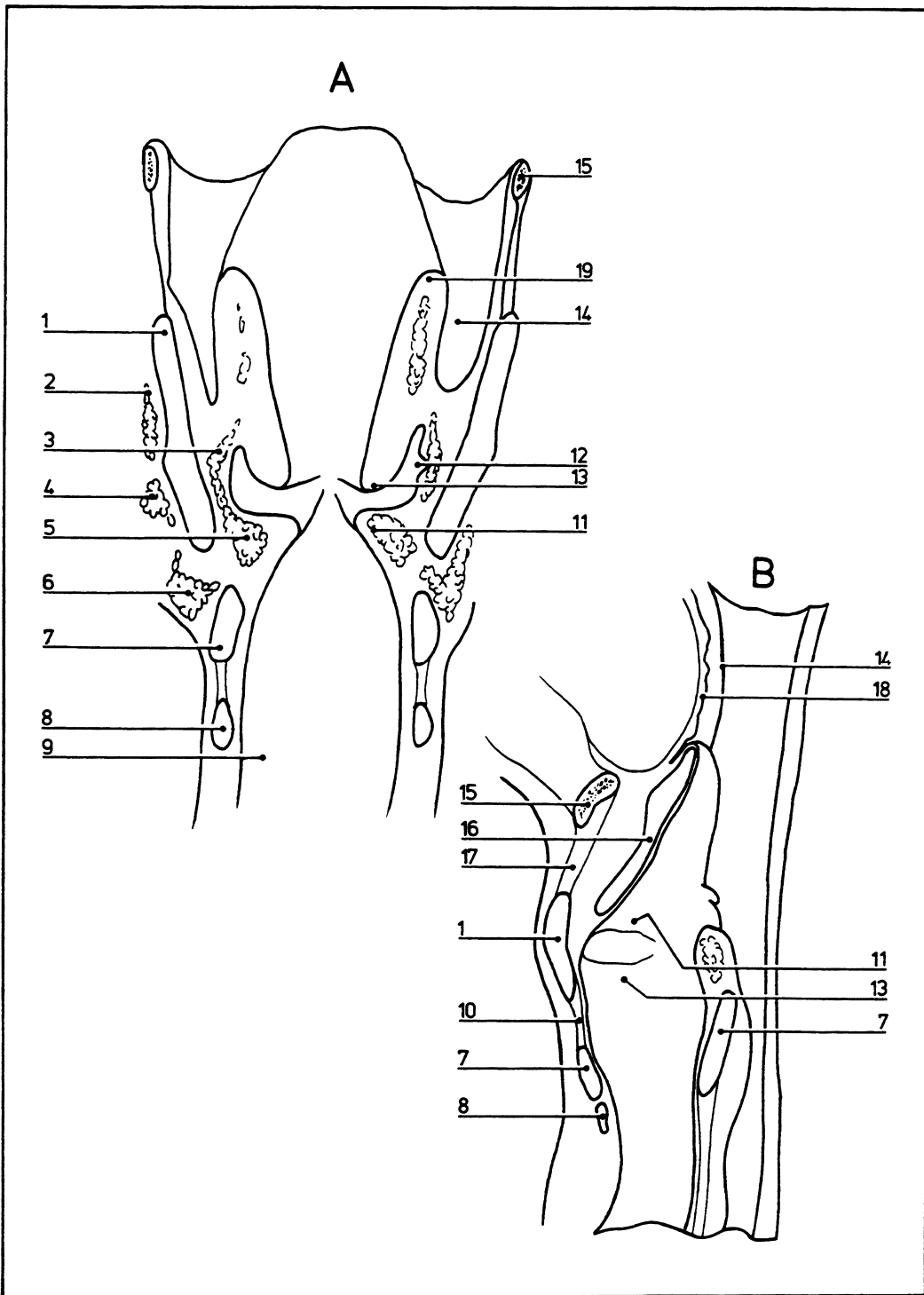


# Larynx: 1

07.014



- |                                   |                                   |                              |
|-----------------------------------|-----------------------------------|------------------------------|
| <b>A</b> Frontal section          | <b>8</b> First tracheal cartilage | <b>18</b> Root of the tongue |
| <b>B</b> Sagittal section         | <b>9</b> Infraglottic cavity      | <b>19</b> Aryepiglottic fold |
| <b>1</b> Thyroid cartilage        | <b>10</b> Cricothyroid ligament   |                              |
| <b>2</b> Thyrohyoid muscle        | <b>11</b> Vocal fold (vocal cord) |                              |
| <b>3</b> Thyroepiglotticus muscle | <b>12</b> Laryngeal ventricle     |                              |
| <b>4</b> Sternothyroid muscle     | <b>13</b> Vestibular fold         |                              |
| <b>5</b> Vocalis muscle           | <b>14</b> Piriform recess         |                              |
| <b>6</b> Cricothyroid muscle      | <b>15</b> Hyoid bone              |                              |
| <b>7</b> Cricoid cartilage        | <b>16</b> Epiglottis              |                              |
|                                   | <b>17</b> Thyrohyoid membrane     |                              |